



## Postoperative Genitourinary Challenges in Children with Anorectal Malformations: A Prospective Cohort Study Highlighting the Role of Follow-up

Fatemeh Abedi Karjiban<sup>1</sup>, Fariba Jahangiri<sup>2\*</sup>, Mahmoud Salek<sup>2</sup>, Tahereh Chavoshi<sup>3</sup>, Elham Zarei<sup>4</sup>, Mahdi Bassirian<sup>2</sup>

Received: 26 Aug 2025

Accepted: 5 Nov 2025

Published: 19 Jan 2026

### Abstract

**Background:** Anorectal malformations (ARMs) are congenital anomalies frequently associated with genitourinary abnormalities and other developmental defects. Surgical correction commonly involves colostomy, posterior sagittal anorectoplasty (PSARP), or laparoscopic/laparotomy-assisted approaches. This study aimed to evaluate the occurrence of neurogenic bladder and vesicoureteral reflux (VUR) in ARM patients and their associations with ARM type, fistula location, vertebral anomalies, and surgical technique.

**Methods:** This cohort study included 173 children with ARM in the pediatric surgery department of Ali-Asghar Hospital, Iran, from July 2011 to July 2021. Data on genitourinary problems, including urinary tract infections, vesicoureteral reflux, and neurogenic bladder, were gathered from clinical records and follow-up visits.

**Results:** A total of 37 patients were diagnosed with neurogenic bladder and 44 with vesicoureteral reflux. This study stated higher occurrences of neurogenic bladder and reflux in patients who underwent PSARP. Neurogenic bladder was more prevalent in patients with high-type ARM and rectourethral fistula. The highest incidence of recurrent urinary tract infections was observed in boys with high-type ARM. Approximately 8% (14) of patients showed signs of kidney failure that led to chronic kidney failure.

**Conclusion:** Statistical evaluation of genitourinary issues in patients with ARM who underwent surgery at our center underscores the importance of informing parents of the need for regular follow-up. Given that some of these issues may lead to delayed adverse effects on kidney function, early diagnosis and timely intervention are crucial for preventing complications and slowing the progression to kidney failure and end-stage renal disease (ESRD).

**Keywords:** Anorectal Malformation, Postoperative Complications, Urinary Tract Infection, Vesicoureteral Reflux, Neurogenic Bladder

\*This work has been published under CC BY-NC-SA 4.0 license.

Copyright© Iran University of Medical Sciences

**Cite this article as:** Abedi Karjiban F, Jahangiri F, Salek M, Chavoshi T, Zarei E, Bassirian M. Postoperative Genitourinary Challenges in Children with Anorectal Malformations: A Prospective Cohort Study Highlighting the Role of Follow-up. *Med J Islam Repub Iran.* 2026 (19 Jan);40:7. <https://doi.org/10.47176/mjiri.40.7>

### Introduction

Anorectal malformation (ARM) is a congenital disability involving abnormal development of the distal rectum and anus, occurring in approximately 1 in 5000 live births (1, 2). The ARM classification is based on the position of the malformed gut in relation to the pelvic floor. An ARM on top of the pelvic floor is called a high ARM, while intermediate and low types are at the level of and below

the levator ani muscle (3). Up to 70% of newborn infants with ARM also have concomitant congenital anomalies (4). VACTERL anomalies are a group of congenital malformations—including spinal cord abnormality (V), GI tract atresia (A), congenital heart disease (C), tracheo-oesophageal fistula (T), genitourinary tract abnormality (R), and limb deformity (L). Genitourinary tract abnor-

Corresponding author: Dr Fariba Jahangiri, [Jahanf89@gmail.com](mailto:Jahanf89@gmail.com)

<sup>1</sup> School of Medicine, Iran University of Medical Sciences, Tehran, Iran

<sup>2</sup> Department of Pediatric Surgery, Ali -Asghar Children's Hospital, School of Medicine, Iran University of Medical Sciences, Tehran, Iran

<sup>3</sup> Department of Anesthesiology, School of Medicine, Iran University of Medical Sciences, Tehran, Iran

<sup>4</sup> Department of Radiology, Ali - Asghar Children's Hospital, School of Medicine, Iran University of Medical Sciences, Tehran, Iran

#### ↑What is “already known” in this topic:

Children with anorectal malformation (ARM) frequently develop urogenital complications such as neurogenic bladder, vesicouretero reflux, and recurrent UTIs, which can lead to renal deterioration. Neurogenic bladder is a recognized cause, but its predictors and the importance of regular follow-up have not well investigated.

#### →What this article adds:

This study highlights the multifactorial nature of neurogenic bladder and reflux in ARM, showing that no single clinical factor independently predicts their occurrence. It emphasizes the importance of early detection of these issues, along with spinal anomalies and long-term urological follow-up, to mitigate the progression of renal complications.

malities are the most common abnormalities, occurring in 40% to 50% of cases (2, 5, 6). Long-term follow-up studies reveal that patients with ARM experience urological problems, including urinary incontinence, lower urinary tract dysfunction, and vesicoureteral reflux, at rates ranging from 12% to 24% (7), leading to recurrent urinary tract infections, chronic kidney disease (CKD), and ESRD (8). Urogenital problems pose a serious threat to the kidneys, becoming a primary cause of morbidity and mortality in the long term (9). High-type ARM patients may face renal failure-related mortality rates as high as 6% (10).

The prophylactic use of antibiotics in ARM patients with early diagnosed vesicoureteral reflux may help prevent renal scarring and damage (11). Early diagnosis and proper intervention have demonstrated an excellent prognosis for patients with genitourinary tract anomalies associated with ARM (12), which has a high impact on patients' quality of life, especially their psychological health (13). While numerous studies have reported postoperative complications in ARM patients, their long-term impact has not received sufficient attention. This study aimed to investigate the prevalence and predictors of neurogenic bladder and vesicoureteral reflux in children born with ARM over a 10-year follow-up period, emphasizing the need for continued monitoring to prevent and manage potential complications.

### Methods

This cohort study included all pediatric patients diagnosed with ARM who underwent surgical intervention and were admitted to the Department of Pediatric Surgery at Ali-Asghar Hospital, Tehran, Iran, between 2011 and 2021.

Data collection involved a comprehensive review of inpatient records, referral clinical files, and interviews. During the interviews, the patients and parents were asked about any new symptoms and postoperative complications. Informed consent was obtained from all participants' parents or legal guardians. The nature, purpose, potential risks, and benefits of the study were thoroughly explained, and participation was entirely voluntary. Participants and their legal guardians or parents were informed that they could withdraw from the study at any time without any consequences. Follow-up was conducted until 2024. Under the supervision of experienced pediatric nephrologists and surgeons, patients underwent additional imaging, including ultrasounds, voiding cystourethrography (VCUG), dimercaptosuccinic acid scan (DMSA) scans, and urodynamic studies if needed. Importantly, these additional assessments did not incur any extra costs beyond their regular follow-up care (objective). For children who did not attend follow-up appointments, data were supplemented using information obtained from their parents and data documented in their previous medical records (subjective). All children born with ARM at our referral center undergo a comprehensive preoperative evaluation. This includes cross table prone lateral X-ray (For patients who did not exhibit signs of a perineal fistula or pass meconium in the urine within 18 hours after birth), limb X-ray, echocardiography, sacral X-ray (AP and lateral views), urinary tract

and bladder ultrasonography, and spinal and pelvic imaging included ultrasonography for infants <3 months, and magnetic resonance imaging for those >3 months or in cases where ultrasonographic findings were abnormal. If ultrasound findings are abnormal, such as bladder trabeculation, increased bladder wall thickness, or hydronephrosis, a VCUG is performed. In patients who have undergone colostomy, we routinely perform VCUG before anorectoplasty, even when ultrasound findings are normal. Patients' data—including demographic data (age and sex), and clinical information, the presence and location of the fistulas-perineal fistula, rectourethral fistula, rectovesical fistula, rectovaginal fistula, vestibular fistula, anal stenosis, rectal atresia/stenosis, others-based on the Krick-enbeck classification (14), the type of ARM (high or low, determined by the location of the rectal gas shadow in prone X-rays, measured as more or less than 1 cm from the perineal region or observation of a fistula in the examination of the perineum or vestibule), surgical procedure, and the urogenital problems including urinary tract infection (UTI): defined based on a positive urine culture documented in the patient's medical records included a bacterial count exceeding 100,000 CFU/mL in a clean-catch urine sample, >10,000 CFU/mL in specimens obtained via intermittent catheterization, or the presence of any bacterial colonies in samples collected through suprapubic bladder aspiration. Neurogenic bladder: clinically diagnosed as bladder dysfunction or loss of bladder control due to damage to the brain, spinal cord, or nervous system, based on the patient's medical history and paraclinical results like urodynamic studies. Vesicoureteral reflux (VUR): characterized by the backward flow of urine from the bladder to the ureters or kidneys, identified through paraclinical assessments such as ultrasounds, VCUG, and direct radionuclide cystography (DRNC). Recurrent UTI was defined as either 2 episodes within 6 months or 3 episodes over 1 year, as documented in the follow-up records.

### Statistical Analysis

We utilized the chi-square test for categorical variables as a univariate analysis to assess associations between clinical factors and postoperative genitourinary outcomes, including vesicoureteral reflux (VUR) and neurogenic bladder (NB). Variables with  $P < 0.10$  in the univariate analysis were entered into a multivariate logistic regression model to identify independent predictors. As only the neurogenic bladder showed significant associations in the univariate analysis, multivariate logistic regression was performed with NB as the dependent variable. Independent variables included ARM type, vertebral anomalies, fistula location, and anorectoplasty type. For categorical predictors with >2 categories, dummy variables were created. Statistical analyses were performed using SPSS Version 26.  $P \leq 0.05$  was considered statistically significant. Results are presented as odds ratios (ORs) with 95% confidence intervals (CIs). This study employed both descriptive and analytical statistical methods. Clear tables and informative graphs were used to present the data.

## Results

### Patients

Of the 193 patients with ARM, 14 had undergone ano-rectoplasty at other centers and were referred to us for UTI or reflux. Since their preoperative evaluations were not conducted at our center, they were excluded from the study. Additionally, 6 patients were lost to follow-up as they did not respond to phone calls or attend scheduled visits. A total of 173 patients underwent surgery for ARM at our center, comprising 55 females (31.8%) and 118 males (68.2%). The mean follow-up duration was 1571.4 days (1303.1-1839.7). Also, 98 patients (56.6%) had high-type ARMs; 91 were boys (77.1%), and 7 were girls (12.7%). At the same time, 75 patients (43.4%) had a low type, including 27 boys (22.9%) and 48 girls (87.3%). We found a significant association between sex and high-grade ARM ( $P < 0.001$ ; OR, 0.043; 95% CI, 0.018-0.107). Also, 16 patients had vertebral anomalies, including 7 cases of sacral agenesis, 2 cases of tethered cord, 1 case of hemisacrum, 1 case of hemivertebrae, 1 case of scoliosis, 3 cases of scoliosis with hemivertebrae, and 1 case of scoliosis and hemivertebrae. Among the 3 patients, 9 had high-type ARM, and 7 had low-type. However, the relationship between associated vertebral anomalies and the type of ARM was not statistically significant ( $P = 0.973$ ; OR, 1.018; 95% CI, 0.361-2.871). While sorting the data, 23 male patients (13.2%) had undescended testicles (UDTs), with 8 on the right side, 8 on the left side, and 7 bilateral cases. Notably, among girls, the most prevalent type of fistula was vestibular, followed by perineal. Conversely, among boys, rectourethral fistula was the most common type, followed by perineal fistula (Table 1).

### Surgery

Among 173 ARM patients, 108 (98 girls with high-type and 10 girls with low-type ARM) underwent colostomy based on clinical and surgical assessment. In comparison, 65 low-type patients (27 boys, 38 girls) were managed without colostomy. In these cases, ano-rectoplasty was performed within 48 to 72 hours of birth. For other patients, ano-rectoplasty was performed 2 to 3 months after birth, with timing determined by factors including patient age, surgeon assessment, ARM type, and associated anomalies. Patients with rectovesical fistulas underwent laparoscopic or laparotomically assisted ano-rectoplasty. Overall, 93 colostomy patients underwent PSARP, 15 had laparoscopic-assisted ano-rectoplasty, and 65 low-type patients had primary PSARP without previous colostomy.

## Outcomes

### Vesicoureteral Reflux

In this study, 44 patients were diagnosed with vesicoureteral reflux through ultrasound, VCUG, and DRNC scan. Also, 20 patients had low-type ARM, and 24 had high-type ARM. Vesicoureteral reflux was observed in 17 female patients (1 with cloacal malformation and 16 with low-type ARM) and 27 male patients (18 with rectourethral fistulas, 5 with rectovesical fistulas, and 4 with low-type ARM). Notably, vesicoureteral reflux was most prevalent in patients with rectourethral fistulas. In the colostomy group, reflux was present in 23 patients who underwent PSARP and 5 patients who underwent laparoscopic-assisted Ano-rectoplasty. In the noncolostomy group, reflux was identified in 16 patients with primary PSARP. A total of 39 patients had no associated vertebral anomalies, while 5 exhibited at least 1—3 with sacral agenesis, 1 with hemivertebrae, and 1 with scoliosis accompanied by hemivertebrae.

### Neurogenic Bladder

A total of 37 patients were diagnosed with neurogenic bladder. At the initial evaluation, 7 patients showed abnormal findings on prenatal (fetal) ultrasound, such as signs of hydronephrosis. These abnormalities were confirmed after birth through ultrasound and VCUG, leading to a diagnosis of Neurogenic bladder based on features like bilateral hydronephrosis, increased bladder wall thickness, or urinary retention. Among the remaining 30 patients, the neurogenic bladder was detected in 7 during the preoperative evaluation before Ano-rectoplasty. During the follow-up after ano-rectoplasty, 23 patients developed recurrent urinary tract infections, incontinence, and dribbling beyond the age of 4, despite having normal findings in their initial preoperative evaluations. Based on these symptoms, VCUG and urodynamic studies were performed, ultimately confirming the diagnosis of Neurogenic bladder. Seven patients had concomitant vertebral anomalies (sacral agenesis). Neurogenic bladder was identified in 11 female patients (5 with cloacal malformations and 6 with low-type ARM) and 26 male patients (18 with rectourethral fistulas, 4 with rectovesical fistulas, and 4 with low-type ARM), with the majority of cases linked to rectourethral fistulas. Ten patients with low-type ARM and 27 with high-type ARM were diagnosed with neurogenic bladder. In the noncolostomy group, neurogenic bladder was observed in 8 patients who underwent primary PSARP. In the colostomy group, neurogenic bladder

Table 1. Distribution of Fistula Types in Patients with Anorectal Malformations by Gender. Data are presented as numbers (%)

Fistula classification	Fistula classification								Total
	Cloaca	Perineal f.	Rectourethral f.	Rectovesical f.	Vestibular f.	Rectovaginal f.	Rectal atresia	w/o fistula	
Male	0 (0.0%)	17 (14.4%)	74 (62.7%)	15 (12.7%)	0 (0.0%)	0 (0.0%)	2 (1.7%)	10 (8.5%)	118
Female	5 (9.1%)	11 (20.0%)	0 (0.0%)	0 (0.0%)	37 (67.3%)	1 (1.8%)	1 (1.8%)	0 (0.0%)	55
Total	5 (2.9%)	28 (16.2%)	74 (42.8%)	15 (8.7%)	37 (21.4%)	1 (0.6%)	3 (1.7%)	10 (5.8%)	173

was noted in 25 patients who underwent PSARP and 4 who underwent laparoscopic-assisted anorectoplasty.

Kidney failure progressing to CKD occurred in 14 patients (8%), all of whom had neurogenic bladder, representing 37.8% of neurogenic bladder cases. Among them, 2 patients (aged 9 and 10 years) progressed to end-stage renal disease and required kidney transplantation. The 10-year-old patient had missed several follow-up visits before deterioration. Four patients required placement of peritoneal dialysis catheters during the study period. The remaining 8 patients exhibited laboratory or clinical features of CKD, including elevated serum creatinine, proteinuria, and peripheral edema. They were managed conservatively under regular nephrology follow-up throughout the study period. Progression to end-stage disease beyond the study

follow-up could not be confirmed.

Recurrent UTIs were most common in male patients who underwent PSARP with colostomy, particularly among those with reflux or neurogenic bladder (Figure 1).

The relationship between reflux, neurogenic bladder, and the aforementioned variables is detailed in Table 2.

These results show the importance of considering these factors thoroughly when evaluating potential postoperative problems in patients with ARM. In univariate analysis, neurogenic bladder was significantly associated with ARM type ( $P = 0.024$ ), vertebral anomalies ( $P = 0.022$ ), and fistula location ( $P = 0.001$ ). These variables were entered into the multivariate logistic regression model, along with Anorectoplasty type ( $P = 0.078$ ). Although these variables showed associations in univariate analysis, none

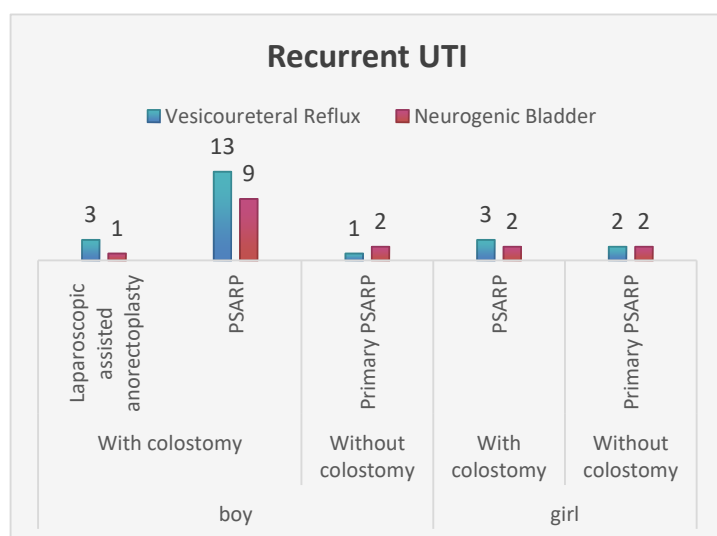


Figure 1. Distribution of recurrent urinary tract infections (UTIs) in relation to gender, surgical technique, and presence of colostomy. The chart categorizes cases by Vesicoureteral reflux (blue) and Neurogenic bladder (red) across different surgical interventions: Laparoscopic-assisted Anorectoplasty, PSARP (posterior sagittal Anorectoplasty), and Primary PSARP. The data is stratified by gender (boys and girls) and whether the procedure was performed with or without a colostomy. The highest incidence was observed in boys who underwent PSARP with a colostomy, particularly in patients with vesicoureteral reflux.

Table 2. Association of Vesicoureteral reflux and Neurogenic bladder with Clinical Variables in Patients with Anorectal Malformations.

variable	Vesicoureteral reflux		Neurogenic bladder	
	P value	OR (95% CI)	P value	OR (95% CI)
Gender	0.259	0.663 (0.324-1.356)	0.761	1.130 (0.512-2.494)
ARM type	0.745	1.121 (0.563-2.232)	0.024	0.405 (0.182-0.900)
Vertebral anomalies	0.575	1.375 (0.450-4.204)	0.022	0.304 (0.105-0.881)
Anorectoplasty type	0.763		0.078	
Location of fistula	0.492		0.001	

\*  $P < 0.05$

Table 3. Multivariate Logistic Regression for Predictors of Neurogenic Bladder

Predictor	P value	OR(95% CI)	
ARM type (Low vs high)	1.000	0.677(0.000 - .)	
Vertebral anomalies (Yes vs no)	0.838	1.152(0.296 - 4.473)	
Anorectoplasty type	0.922		
	Laparoscopic vs PSARP	1.000	—
	Limited vs PSARP	0.687	0.677(0.102 - 4.506)
Location of fistula	1.000		
	Cloaca vs w/o	0.999	—
	Perineal vs w/o	0.999	—
	Rectourethral vs w/o	1.000	1.000(0.000 - .)
	Rectovesical vs w/o	1.000	—
	Vestibular vs w/o	0.999	—

\* OR = Odds ratio; CI = Confidence interval; PSARP = Posterior sagittal anorectoplasty. Unrealistic OR values are due to small subgroup sizes and quasi-complete separation; we report them as "—",  $P < 0.05$

of them independently predicted the presence of neurogenic bladder (all  $P > 0.05$ ; Table 3). The wide confidence intervals observed for some fistula subtypes likely reflect small subgroup sizes and sparse data, which may have limited the model's power to detect significant effects.

### Discussion

Urogenital complications in patients with ARMs can profoundly affect both the physical health and psychological well-being of children and their families. Although previous studies have examined these outcomes, the importance of regular follow-up visits remains underexplored. In this cohort, genitourinary issues were assessed through urodynamic studies, imaging, medical history, and family-reported data. These complications, particularly urinary incontinence and UTIs, may lead to psychological distress and progressive renal deterioration, with CKD reported in up to 5.7% of patients, all of whom had high-type ARM (8). The highest risk was observed in cases with recto-bladder neck fistula (9). In our study, we found the highest incidence in patients with rectourethral fistula. Renal function decline in ARM likely results from a combination of congenital anomalies, recurrent infections, and neurogenic bladder dysfunction (1). Neurogenic bladder in ARM may arise from 3 primary mechanisms: (1) congenital anomalies affecting urinary tract development; (2) neurological consequences of vertebral or spinal malformations, such as sacral agenesis or tethered cord; and (3) surgical factors related to reconstruction or nerve injury (15, 16). In our cohort, while univariate analysis identified several factors potentially associated with neurogenic bladder, these relationships did not remain significant in the multivariate model, suggesting no single independent predictor after adjusting for confounders, such as ARM type, fistula subtype, vertebral anomalies, and surgical approach.

Our findings align with those of Goossens et al, who reported that up to 52% of patients with anorectal malformations have associated urological anomalies, with the frequency increasing with malformation complexity—the more complex the anomaly, the higher the risk of urological complications (7). Similarly, our study demonstrated a higher incidence of urogenital dysfunction among patients with high-type ARM. Neurogenic bladder was 2.7 times more common in this group, likely reflecting the combined effects of coexisting anomalies and possible intraoperative neural injury, particularly in cases involving bladder neck fistulas requiring extensive dissection. The relationship between neurogenic bladder and spinal cord anomalies is well established, with approximately 25% of ARM patients developing neurovesical dysfunction, most frequently in high-type malformations (17, 21, 22). Contributing factors include vertebral or spinal anomalies—present in nearly one-third of cases—and possible iatrogenic bladder denervation during repair, especially with transperitoneal approaches. Although PSARP reduces the risk of denervation due to favorable anatomic access, careful dissection remains critical, as neural pathways lie close to the fistula. Furthermore, higher fistula levels, as defined in the Krickbeck classification, may inherently predis-

pose patients to neurogenic dysfunction (22). In males with high-type ARM, the recto-urethral fistula's proximity to the hypogastric plexus further increases the risk of neural injury during perineal dissection (21). Spinal anomalies are strongly associated with lower urinary tract dysfunction (LUTD), observed in 43% of affected patients compared to 8% without spinal abnormalities (7). Long-term studies have also demonstrated LUTD in up to 56% of ARM patients, with 22% showing underlying spinal cord malformations. Notably, dysfunction may also occur in children with apparently normal spinal anatomy, with reported rates of 41%, 29%, and 23% at 5-, 10-, and 15-year follow-ups, respectively (18). In our study, 43.8% (7 of 16) of patients with vertebral anomalies developed neurogenic bladder, confirming a significant association between vertebral abnormalities and urinary dysfunction.

Various previous studies had evaluated surgery outcomes in patients with ARM and neurogenic bladder. Kılıç et al found that, before PSARP, all patients with low-type ARM had normal urodynamic findings, whereas 82% of those with high-type ARM exhibited neurological dysfunction, with no significant postoperative changes in either group (5). Similarly, other studies have shown that PSARP has minimal impact on bladder function, suggesting that surgical intervention itself does not substantially alter bladder function (17). Versteegh et al also noted stable bladder function in 83% of patients after surgery, with 63% achieving complete urinary continence (19). In our study, an association was observed between the incidence of vesicoureteral reflux and neurogenic bladder among different anorectoplasty procedures, which was not statistically significant.

Pandya et al reported that only 57% of patients achieved urinary continence. At the same time, the remainder experienced varying degrees of incontinence, underscoring the need for long-term follow-up and comprehensive urological assessment (20). Consistent with previous studies (7, 16), our findings support proactive evaluation—particularly in high-type ARM—through regular imaging and clinical surveillance to identify subclinical voiding dysfunction, even in patients with less severe ARM, who remain at risk for LUTD. In addition, VUR was observed in 36.3% of newborns with colostomy, with bacteriuria present in 65.5% of those cases, all of whom had loop colostomies (11). This highlights the increased susceptibility to urinary infections during the early postoperative period and the importance of infection control to prevent renal damage. Early identification of neurovesical dysfunction is essential, as progressive upper tract dilatation on ultrasound may signal evolving bladder dysfunction. Although urodynamic studies (UDS) can reveal abnormalities even in asymptomatic patients, their use in infants is limited by invasiveness, interpretation challenges, and technical constraints. Implementing early UDS in high-type ARM patients with minimal ultrasound abnormalities could facilitate timely renal-protective interventions and mitigate long-term complications (21).

Persistent hydronephrosis or recurrent febrile UTIs despite adequate bladder drainage should prompt further evaluation with a voiding cystourethrogram (VCUG) and

consideration of antibiotic prophylaxis. At least yearly multidisciplinary follow-up, including renal and bladder ultrasounds, is essential for monitoring bladder emptying and hydronephrosis, especially in patients with spinal or sacral anomalies, whose urological function may evolve. When poor bladder emptying or neurogenic dysfunction is suspected, UDS or video urodynamic studies (VUDS) should be performed to assess severity. VUR occurs in approximately 30% to 40% of children with ARM and is a major contributor to obstructive uropathy and recurrent infections, both of which can lead to progressive nephron loss. In these cases, individualized management—including clean intermittent catheterization (CIC), vesicostomy, and anticholinergic therapy—helps preserve renal function. CKD and ESRD represent the leading causes of reduced life expectancy in this population. Annual nephrological and urological follow-up, including blood pressure monitoring, urinalysis for proteinuria, and renal and bladder ultrasound, is therefore essential. With modern multidisciplinary care, most patients now survive into adulthood with near-normal life expectancy; however, up to 30% may develop CKD, and nearly 10% require renal transplantation, underscoring the importance of renal surveillance (22).

In our practice, urodynamic studies are selectively performed based on clinical symptoms and ultrasound findings rather than routinely for all patients. Evaluation is prompted by findings suggestive of neurogenic bladder—such as increased bladder wall thickness, a posterior urethral valve-like appearance, elevated postvoid residuals, or the presence of sacral or vertebral anomalies—or by symptoms such as recurrent urinary tract infections or incontinence. Although urodynamic testing can technically be performed at any age per the textbook, we typically conduct it after 3 years of age, when the child can follow instructions and cooperate, ensuring more reliable results.

Taken together, these findings suggest that neurogenic bladder and reflux in ARM patients likely result from a multifactorial process involving neural, anatomical, and iatrogenic contributors, rather than any single clinical feature. This reinforces the need for long-term urological surveillance in all ARM patients, regardless of anatomical subtype or surgical technique, to ensure early identification and management of urinary dysfunction. Despite the relatively small cohort, our results underscore the importance of early detection of spinal cord anomalies and consistent postoperative close follow-up to prevent long-term renal and bladder complications. Regular postoperative evaluations are essential for screening for urological issues and monitoring bladder function over time. This proactive approach safeguards both the bladder and kidneys, facilitates early intervention, and can help prevent or delay problems such as ESRD.

Despite the valuable insights gained, this study has several limitations. The absence of a control group limits the interpretability of results, and the small sample size—especially for some variables—may have weakened observed correlations. As a single-center study, the generalizability of our findings is limited; extended multicenter studies are recommended. In addition, some information

provided by parents may have been affected by recall bias, as unawareness of the disease or its complications might have delayed clinical visits or caused inaccuracies in interview data. This could be mitigated by emphasizing objective paraclinical findings (eg, ultrasound, VCUG, scans) and thorough parental education. The study did not focus on bowel factors such as fecal incontinence and constipation, despite their well-established link to LUTD. (18) Due to the study design, this relationship remains underexplored and should be addressed in future research. Although no direct association between UDT and ARM was observed, further studies are needed to assess potential impacts on urogenital outcomes.

### Conclusion

This study highlights a higher incidence of neurogenic bladder and vesicoureteral reflux in patients undergoing PSARP, particularly among those with high-type anorectal malformations and rectourethral fistulas. Male patients who underwent both colostomy and PSARP were especially prone to recurrent urinary tract infections. Continuous parental education and structured follow-up are essential to ensure early detection and intervention, as complications may arise even after an initially normal assessment. Discontinuation of follow-up within the first few years of life may delay recognition of critical renal issues. Given the significant impact these conditions have on both patients and their families' quality of life, annual follow-up, at least until puberty, is strongly recommended to enable timely management and prevent or delay severe outcomes such as renal failure.

### Acknowledgment

N/A.

### Conflict of Interests

The authors declare that they have no competing interests.

### Authors' Contributions

Fatemeh Abedi Karjiban contributed to data curation, analysis, and drafting of the manuscript. Mahdi Bassirian contributed to manuscript review and editing. Fariba Jahangiri contributed to conceptualization, methodology, project administration, and manuscript review and editing. Mahmoud Salek contributed to supervision and manuscript review, editing, and revision. Tahereh Chavoshi contributed to supervision, manuscript review, editing, and revision. Elham Zarei contributed to supervision and manuscript review, editing, and revision.

### Ethical Considerations

Following approval from the Ethics Committee of Iran University of Medical Sciences, the research commenced under the ethical code IR.IUMS.FMD.REC.1401.128. The procedures used in this study adhere to the tenets of the Declaration of Helsinki. Informed consent was obtained from patients' legal guardians or parents.

### Funding Support

N/A.

### Data Availability

The dataset generated and analyzed during the current study is not publicly available due to patient privacy and institutional ethical restrictions. De-identified data are available from the corresponding author upon reasonable request.

### AI Use Statement

During the preparation of the manuscript artificial intelligence tool ChatGPT was used solely to assist with language editing and grammatical refinement. Following its use, the authors reviewed and edited the content and take full responsibility for the content, scientific accuracy, and integrity of the article.

### References

- Giuliani S, Midrio P, De Filippo RE, Vidal E, Castagnetti M, Zanon GF, et al. Anorectal malformation and associated end-stage renal disease: management from newborn to adult life. *J Pediatr Surg*. 2013;48(3):635–41.
- Levitt MA, Peña A. Anorectal malformations. *Orphanet J Rare Dis*. 2007;2(1):33.
- Stephens FD, Smith ED. Classification, identification, and assessment of surgical treatment of anorectal anomalies: Report of a work meeting held on May 25<sup>th</sup> 1984, at Wingspread? Convention Center, The Johnson Foundation, Racine, Wisconsin, USA. *Pediatr Surg Int* [Internet]. 1986 Nov [cited 2025 May 18];1(4). Available from: <http://link.springer.com/10.1007/BF00177146>
- Bjoersum-Meyer T, Kaalby L, Lund L, Christensen P, Jakobsen MS, Baatrup G, et al. Long-term functional urinary and sexual outcomes in patients with anorectal malformations—a systematic review. *Eur Urol Open Sci*. 2021;25:29–38.
- Kiliç N, Emir H, Sander S, Eliçevik M, Celayir S, Söylet Y. Comparison of urodynamic investigations before and after posterior sagittal Anorectoplasty for anorectal malformations. *J Pediatr Surg*. 1997;32(12):1724–7.
- Rintala RJ, Pakarinen MP. Imperforate anus: long-term and short-term outcomes. In Elsevier; 2008. p. 79–89.
- Goossens W, de Blaauw I, Wijnen M, De Gier R, Kortmann B, Feitz W. Urological anomalies in anorectal malformations in The Netherlands: effects of screening all patients on long-term outcome. *Pediatr Surg Int*. 2011;27:1091–7.
- Ganesan I, Rajah S. Urological anomalies and chronic kidney disease in children with anorectal malformations. *Pediatr Nephrol*. 2012;27:1125–30.
- Bischoff A, DeFoor W, VanderBrink B, Goebel J, Hall J, Alonso M, et al. End stage renal disease and kidney transplant in patients with anorectal malformation: is there an alternative route? *Pediatr Surg Int*. 2015;31:725–8.
- Sharma AK, Kashtan CE, Nevins TE. The management of end-stage renal disease in infants with imperforate anus. *Pediatr Nephrol*. 1993;7:721–4.
- Kim W, Lee S, Seo JM. Vesicoureteral reflux increases the risk of urinary tract infection prior to corrective surgery in newborn males with anorectal malformation. *Pediatr Surg Int*. 2020;36:1495–500.
- Peña A, Iglesias LM, Aprahamian MI, Holcomb AK Jr, Murphy JP. In: Grosfeld JL, O'Neill JA Jr, Coran AG, Fonkalsrud EW, editors. *Pediatric surgery*. 4th ed. Philadelphia: Elsevier Saunders; 2005. p. 496–517.
- Versteegh H, van den Hondel D, IJsselstijn H, Wijnen R, Sloots C, de Blaauw I. Cloacal malformation patients report similar quality of life as female patients with less complex anorectal malformations. *J Pediatr Surg*. 2016;51(3):435–9.
- Holschneider A, Hutson J, Peña A, Beket E, Chatterjee S, Coran A, et al. Preliminary report on the International Conference for the Development of Standards for the Treatment of Anorectal Malformations [Internet]. *J Pediatr Surg*. 2005;40(10):1521–6 [cited 2025 May 18]. Available from: <https://www.sciencedirect.com/science/article/pii/S0022346805006457>
- Cain MP. Anorectal Malformations and Potential Urological Problems—What is the Pediatric Urologist's Role? *J Urol*. 2014;192(6):1597–8.
- Strine A, VanderBrink B, Alam Z, Schulte M, Noh P, DeFoor Jr W, et al. Clinical and urodynamic outcomes in children with anorectal malformation subtype of recto-bladder neck fistula. *J Pediatr Urol*. 2017;13(4):376. e1–376. e6.
- Borg H, Holmdahl G, Olsson I, Wiklund LM, Sillén U. Impact of spinal cord malformation on bladder function in children with anorectal malformations. *J Pediatr Surg*. 2009;44(9):1778–85.
- Borg H, Holmdahl G, Doroszkiewicz M, Sillen U. Longitudinal study of lower urinary tract function in children with anorectal malformation. *Eur J Pediatr Surg*. 2014;24(06):492–9.
- Versteegh HP, Wolffenbuttel KP, Sloots CE, Madern GC, van den Hoek J, Wijnen RM, et al. Effects of reconstructive surgery on bladder function in patients with anorectal malformations. *J Urol*. 2014;192(6):1789–93.
- Pandya KA, Koga H, Okawada M, Coran AG, Yamataka A, Teitelbaum DH. Vaginal anomalies and atresia associated with imperforate anus: diagnosis and surgical management. *J Pediatr Surg*. 2015;50(3):431–7.
- Binu V, Dash V, Bawa M, Kanojia RP, Samujh R. Role of urodynamics in male patients of high-anorectal malformations: a prospective study. *Pediatr Surg Int* 2021;37:461–8.
- Harris KT, Wilcox DT. Management of the urological tract in children with anorectal malformations – a contemporary review. *Ther Adv Urol*. 2023;15.